Mrs X (age: 71)

CASE PRESENTATION

Aftab Butt DCT2 Restorative Dentistry

HISTORY

CO & HPC: Upper bridge (Two unit conventional cantilever bridge replacing UR1) is "annoyingly wobbly" and the mobility is "uncomfortable but not painful". The bridge was fitted 15 years ago after UR1 extracted following trauma. Bleeding on brushing. No pain from any teeth on biting or any other stimulus.

MH: Fit and well, no medications, no known allergies

SH: non-smoker, mother lost all teeth by age of 40

DH: Irregular attender at previous GDP for previous 20 years: left her GDP

OH: Patient brushes twice daily with manual toothbrush and fluoride toothpaste, no interdental cleaning aids or other sources of fluoride. Pt demonstrates an aggressive scrubbing brushing technique.

EXAMINATION

E/O: Nothing abnormal detected: lymph nodes, TMJ, facial symmetry

I/O: Tongue, hard palate, soft palate, buccal/labial mucosae, floor of mouth nothing abnormal detected. Gingivae: generalised recession, firm texture, pink appearance, blunting of interdental papillae. Plaque score 65%.. Generalised calculus on interdental surfaces. Signs of attrition on most teeth and cervical abrasion cavities on posterior teeth. Mesial surface of UL8: brown carious lesion, hard and smooth to probe indicating arrested caries. LR7 occlusal amalgam fracture which catches on probe.

BPE scores:

4	4	4
4	4	4

BEWE:

2	2	2
2	2	2

Total score 12: medium risk

CHARTING

6 Point Pocket Charts

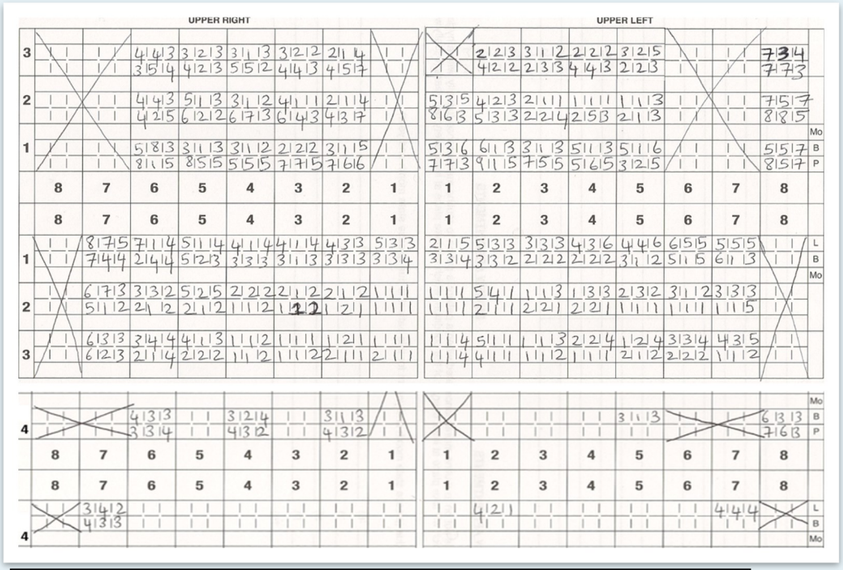

1- Initial baseline 6 point pocket chart
2- At review, after completion of first round of root surface debridement
3- At review, after completion of second round of root surface debridement 8/52 later
4- Pocket depths of pockets previously >4mm after third debridement of these pockets

SPECIAL INVESTIGATIONS - Radiographs

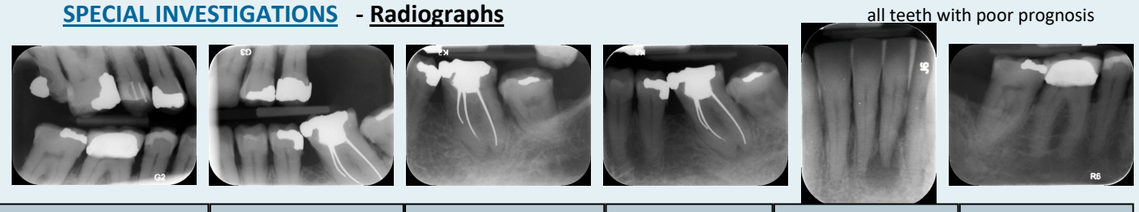

Right Bitewing -Periodontal bone loss – UR7 large crown radiolucency- extracted before Pt presented to me—UR5 dentine pins

Left bitewing – Periodontal bone loss – LL7 Root filled (silver points)

LCPA LL7 ,LL8 – ~50% bone loss distal LL7 - ~30% bone loss mesial LL8 – LL7 PA radiolucency

LCPA LL4, LL5, LL7 – mild bone loss LL4 and LL5 – LL7 PA radiolucency under both roots

LCPA LR2, LR1, LL1, LL2 – 50-60% bone loss around LR1 and LR2 – LL1 >80% bone loss and periapical radiolucency

LCPA LR5, LR6, LR7 – 30% bone loss LR5 and LR6 – ~80% of one cortical plate distal of LR7

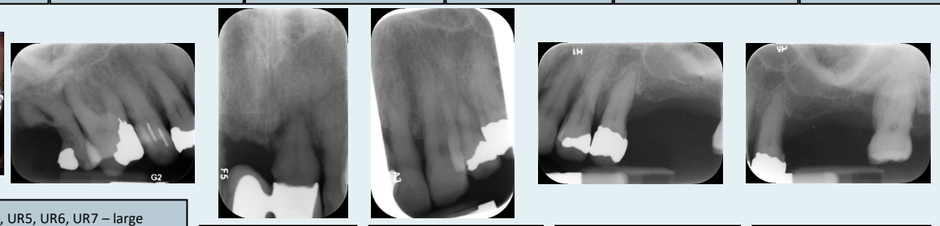

LCPA UR4, UR5, UR6, UR7 – large crown radiolucency UR7 (has been extracted) – Vertical bone loss distal (~95%) and mesial (50%) UR6, unclear if any periapical pathology UR6 – 20% bone loss UR5 – 30% bone loss UR4

LCPA UL1 & UR1 pontic – UL1 ~100% bone loss: radiolucency extending to periapical area

LCPA UL2, UL3, UL4, UL5 –~ 50% bone loss around UL2 - ~20% bone loss UL3 – Other bone levels unclear

LCPA UL3, UL4, UL5 - ~30% bone loss UL4 - ~70% bone loss distal UL5

LCPA UL8: - ~80% bone loss mesial UL8 – ~60% distal bone loss UL8 with widening of the distal crestal PDL

PRE-OP PHOTOS:

Sensibility Tests

Endofrost: UR6, UR5, UL8, LL2, LL8, LR1, LR2 – Positive response
UL1 and LL1 – no response

EPT Values: UR6 – 46, UR5- 38, UL8- 52, LL2- 39 , LL8- 43, LR1- 30
UL1 and LL1 – no response to EPT

Percussion Testing: UL8, LL2, LL1, LR1, LR2, LL7 and LL8 - NOT TTP
UL1 – slightly TTP

Mobility Grades: **Grade 3:** UL1
Grade 1: UR6, UR2, UL2, UL5, LL7, LL2, LL1, LR1, LR2, UL8

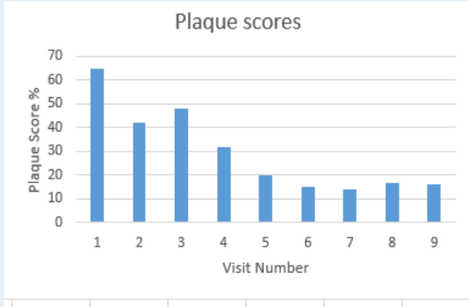

DIAGNOSES

- Generalised periodontitis, Stage IV, Grade C
- Aetiology: Poor OH, Family history of periodontal disease

- UL1 (Hopeless prognosis) - severe periodontal bone loss and loss of vitality. Primarily perio perio-endo lesion or chronic periapical periodontitis subsequent to trauma to teeth
- LL1 (Poor prognosis) – Severe periodontal bone loss and loss of vitality. Chronic periapical periodontitis (trauma) or possible primarily perio perio-endo lesion
-UL8 (Poor prognosis) – severe periodontal bone loss and mobility. UL8 mesial arrested caries.
-LL7 (Poor prognosis) - Refractory periapical periodontitis
-UR6 (Poor prognosis)– Severe periodontal bone loss: unclear from LCPA if periodontal bone loss has extended to apices of teeth. (However, UR6 has consistently given a positive normal response to sensibility testing and showing no other signs of loss of vitality.
- LR7 occlusal amalgam fracture
- Toothwear– attrition (most likely physiologic) and abrasion (likely linked to aggressive toothbrushing technique)

TREATMENT PROVIDED

- **Acute Phase**: nil required, pt presented without pain or other acute conditions
- **Stabilisation phase:** - OHI (including non-aggressive toothbrushing) and diet advice, - Fluoride varnish UL8 mesial arrested caries lesion, - Extirpation LL1, - Non-Surgical Periodontal treatment (including quadrant by quadrant RSD), - XLA UL1 and placement of immediate denture replacing UL1 & UR1 (acrylic spoon denture) - Repair LR7 fractured amalgam w/ composite - Options regarding LL7 explained to patient: she wishes to do nothing for now as tooth is symptomless
- **Review:** of immediate denture, periodontal condition and active surveillance of UR6 pulp vitality, including LCPA shown below. No signs of loss of vitality of UL6 found thus far
- **Definitive Treatment:** - Completion LL1 RCT - Replacement of immediate denture with 4-unit fixed-fixed minimal preparation bridge to replace upper central, with only minimal preparation of upper lateral abutment teeth within enamel (180 degree wrapa-round design)
- **Future Maintenance:** Periodontal maintenance and active surveillance of all teeth with poor prognosis

Post-op LL1 RCT

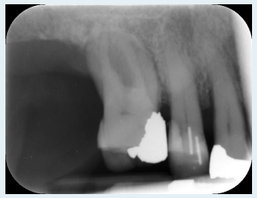

Review LCPA UR6– ~90% distal bone loss UR6, unclear if any periapical pathology, no obvious crown radiolucencies

POST-OP PHOTOS: